

# Management of Noonan Syndrome

## A Clinical Guideline

Noonan Syndrome Guideline Development Group



# Contents

Introduction	3
... to Noonan Syndrome	3
... to the Noonan Syndrome Guidelines Development project	3
... to the Noonan Syndrome Clinical Management Guidelines	3
<b>Diagnosis and clinical features of Noonan Syndrome</b>	<b>4</b>
<b>Recommended baseline investigations in Noonan Syndrome</b>	<b>5</b>
<b>Recommendations for the Management of Noonan Syndrome</b>	<b>6</b>
... in neonates & infancy	6
... in childhood	8
... in adolescence	11
... in adulthood	13
<b>Noonan Syndrome Growth Charts</b>	<b>15</b>
... Boys— Length for Age and Weight for Length: 0–36 months	15
... Girls— Length for Age and Weight for Length: 0–36 months	16
... Boys— Stature and Growth Velocity for Age: 2–20 years old	17
... Girls— Stature and Growth Velocity for Age: 2–20 years old	18
<b>References</b>	<b>19</b>
<b>Information for Parents</b>	<b>29</b>
<b>Acknowledgements</b>	<b>30</b>

## Introduction...

### ... to Noonan Syndrome (NS)

Noonan syndrome (NS) is one of the more common genetic conditions.

The incidence of NS is estimated as 1 in 1,000 to 1 in 2,500 births, so it is still a relatively rare condition.

The severity of NS is the same in males and females.

The main features are congenital heart defects, short stature and characteristic facial features.

Early motor delay associated with hypotonia is not necessarily associated with later learning difficulty, and most adults with NS are able to lead independent autonomous lives.

### ... to the Noonan Syndrome Guideline Development Project

The guidelines have been developed using a robust methodology based on the one utilised by the Scottish Intercollegiate Guidelines Network (SIGN). The method has been adapted to suit rare conditions where the evidence base is limited, and where expert consensus plays a greater role. The members of the guideline development group are listed on page 30.

### ... to the Noonan Syndrome Clinical Management Guidelines

#### What are the aims of the guidelines?

The guidelines aim to provide clear and wherever possible, evidence-based recommendations for the management of patients with Noonan syndrome.

#### Who are they aimed at?

These guidelines are provided for people with NS to use with their primary care and specialist clinicians as many healthcare professionals will not have had personal experience of managing Noonan syndrome. As it is a multisystem disorder, people with NS may require various tests, screening, assessments, referrals and multidisciplinary interventions at different stages of their lives. These guidelines lay out these requirements in a clear format that is accessible to anybody who is involved in the care of an individual with NS.

#### How are they organised?

The guidelines are divided into recommendations for four age groups:

- Neonatal and Infancy—0—1 years old - Childhood: 1—11 years old - Adolescence: 11—18 years old - Adulthood: 18 years old +

Page 4 contains an overview of the diagnostic criteria and clinical features of NS, and page 5 lists the suggested baseline investigations. Subsequently, the guidelines are organised into specific age groups. For each group, management issues along with any recommended tests/screenings are listed, and follow-up options depending on the outcome of the test or screening are indicated.

NB. ABNL= Abnormal

A full list of references starts on page 19, organised by body system, which can be used as a signpost to further information on specific aspects of NS for healthcare professionals.

Additionally, there is a list of useful contacts for parents and families affected by NS, on page 29.

# Diagnosis and clinical features of Noonan Syndrome

## Diagnostic features of NS (van der Burgt 1997)

Feature	A = Major	B = Minor
1. Facial	Typical face (Facial features of NS vary over time and may have only subtle differences. Expert assessment is therefore Required. See Allanson 1987—full reference p.19).	Suggestive face
2. Cardiac	Pulmonary valve stenosis and/or hypertrophic cardiomyopathy (HCM)	Other cardiac defect
3. Height	< 3th centile	< 10th centile
4. Chest wall	Pectus carinatum/excavatum	Broad thorax
5. Family History	First degree relative with definite NS	First degree relative suggestive of NS
6. Other	Mild developmental delay, cryptorchidism AND lymphatic dysplasia	Mild developmental delay, cryptorchidism, OR lymphatic dysplasia

### Definitive NS:

Criterion 1A +		Criterion 1B +	
One of 2A–6A	Two of 2B–6B	Two of 2A–6A	Three of 2B–6B

\*Currently, mutation testing will prove a diagnosis of Noonan Syndrome in 70% of cases; in 30% the responsible gene remains unknown. The diagnosis of NS should be considered in parents when a child is diagnosed with the syndrome. Given the number of different genes where mutations can cause NS, the appropriateness and sequence of gene testing should be decided by a clinical geneticist.

### Differential diagnoses:

- Cardio-facio-cutaneous syndrome (CFC)
- Costello syndrome
- LEOPARD syndrome
- King-Denborough Syndrome (phenotypically distinct. Malignant hyperthermia is not described in NS)

NB—Neurofibromatosis-Noonan syndrome formed part of the differential diagnosis in the past; it is now known that some patients with either of these conditions will have overlapping clinical features, due to the causative mutations occurring in the same biological pathway.

## Recommended baseline investigations in Noonan Syndrome

Clinical Features of Noonan Syndrome	Baseline investigations
<p>(where an investigation is not indicated for a specific clinical feature, please refer to the relevant age group-specific page for management recommendations)</p>	
<ul style="list-style-type: none"> <li>• Congenital heart defects (e.g. pulmonary stenosis, hypertrophic cardiomyopathy, atrial septal defect)</li> <li>• Failure to thrive/slow growth rate/feeding problems</li> <li>• Short stature</li> <li>• Developmental delay and neuropsychological/behavioural issues</li> <li>• Minor renal anomalies</li> <li>• Bleeding disorders</li> <li>• Visual problems (e.g. posterior segment ocular changes and anterior segment ocular abnormalities)</li> </ul>	<ul style="list-style-type: none"> <li>• Full cardiac evaluation at diagnosis.</li> <li>• Monitor and plot growth on appropriate NS and age-based growth chart.</li> <li>• Refer patient in second half of first year or at diagnosis for formal developmental assessment.</li> <li>• Baseline neuropsychological assessment at primary school entry.</li> <li>• Refer for renal ultrasound at diagnosis.</li> <li>• Carry out baseline coagulation screening in patients aged 5+, or earlier if major procedure to be undertaken. (Prothrombin Time (PT) Activated Partial Thromboplastin Time (aPPT) and FXI assay.)</li> <li>• Refer for specialist ophthalmology assessment at the point of diagnosis.</li> </ul>

# Recommendations for the management of Noonan Syndrome

~ *in neonates & infancy (1)* ~

AGE 0-1

Recommended Testing/Screening	Clinical Management Recommendations
• Feeding assessment	Refer for dietary assessment and evaluation of swallowing if needed.
	ABNL → Refer to speech therapist for management if necessary.
	ABNL → Frequent vomiting should prompt investigation for gastro-oesophageal reflux and malrotation.
	ABNL → Treat with anti-reflux measures. Persistent vomiting or food refusal may require tube feeding (although this is rare).
• Full cardiac evaluation	At diagnosis.
	ABNL → If hypertrophic cardiomyopathy (HCM) is found, follow up carefully. Management of congenital heart disease is as per the general population, however a dysplastic valve is more likely and therefore surgery may be more likely to be necessary.
• Growth monitoring	Measure height, weight and occipitofrontal circumference (OFC) at birth and 1-3 monthly.
	Plot on NS-specific growth charts.
	ABNL → Routine paediatric investigations for failure to thrive and reduced growth velocity.
• Neuropsychological and Behavioural Issues	Refer for formal developmental assessment in 2nd half of first year.
	ABNL → Developmental delay caused by hypotonia will improve with occupational and physiotherapy.
	Management of developmental delay will be as per the general population.
• Neurology—potential complications in NS include seizures, craniosynostosis, hydrocephalus and Arnold Chiari Malformation.	Low threshold for investigation of neurological symptoms e.g. consider Arnold-Chiari malformation and hydrocephalus if patient presents with headache or other neurological symptoms, and refer for MRI if suspected.
• Renal ultrasound	ABNL → Refer to paediatric nephrologist for management if renal anomalies are identified in ultrasound at diagnosis.

# Recommendations for the management of Noonan Syndrome

~ *in neonates & infancy (2)* ~

AGE 0-1

Recommended Testing/Screening	Clinical Management Recommendations
• Coagulation screening	To be carried out before any major surgery in neonates/infants, and at least once during childhood.
• Check for cryptorchidism	ABNL → Manage in the standard way at the appropriate time.
• Skin problems: Keratosis Pilaris/Ulerythema	→ Avoid skin dryness, which can be worsened by long hot baths, perfumed soaps and dry atmospheres.
	ABNL → Manage using emollients, keratolytic agents e.g. salicylic acid in urea cream, if tolerated, or short courses of topical steroids if necessary (especially if erythematous). Within a specialist dermatology setting, it should be noted that retinoids may not be a first choice treatment as they have been shown not to work in some NS patients.
• Genetic mutation screening	→ Should be considered in the context of genetic management—which genes are tested for should be decided by a clinical geneticist.
• Vision screening: squint, posterior segment ocular changes and anterior segment ocular abnormalities have been described in NS.	→ Refer for baseline evaluation at point of diagnosis.
	ABNL → Ophthalmic follow up/management as deemed appropriate by the ophthalmologist.
• Hearing assessment	→ Refer for baseline evaluation in 2nd half of first year.
	ABNL → Management in standard way.

**! Anaesthesia**  
*NS can cause coagulation difficulties that should be evaluated prior to surgical procedures so that care, including anaesthesia, can be planned accordingly.*  
*Patients with NS and haemodynamically significant cardiac involvement such as severe hypertrophic cardiomyopathy need to be treated according to the usual principles for patients with such cardiovascular risk factors.*  
*Patients with NS may have craniofacial and/or vertebral anomalies that could affect intubation or the administration of spinal anaesthesia.*

# Recommendations for the management of Noonan Syndrome

~ *in childhood (1)* ~

AGE 1-11

Recommended Testing/Screening	Clinical Management Recommendations
<ul style="list-style-type: none"> <li>Echocardiogram (ECHO)</li> </ul>	<p>Annually until the age of 3 and then at 5 and 10 years old, to assess for onset of HCM.</p> <p><b>ABNL</b> If results indicate HCM, follow-up regularly. Management of congenital heart disease is as per the general population, however a dysplastic valve is more likely and surgery may be more likely to be necessary.</p> <p>If ECHO results are normal at the age of 10 years old and older, cardiac follow up remains necessary due to the ongoing increased risk of cardiomyopathy.</p>
<ul style="list-style-type: none"> <li>Growth assessment</li> </ul>	<p>Nearly half of children with NS will reach a height within the normal range without growth hormone (GH) intervention. Modest response to growth hormone therapy (GHT) has been documented but some NS patients will continue to grow into their late teens/early twenties (because of late puberty) and thereby reach normal range. Final height may also be influenced by parental height. Plot growth on NS growth charts.</p>
<p>Growth hormone (GH) axis evaluation</p>	<p><b>ABNL</b> All children with a height below the mean for NS should be referred to a paediatric endocrinologist for assessment.</p> <p><b>ABNL</b> If height is below 2.5 standard deviations (SD) from the mean on standard childhood charts, GHT may be considered without evaluation of the GH axis. If IGF-1 levels are low, testing of the GH axis should be considered to show growth hormone deficiency (GHD).</p>
<p>GH &amp; hypertrophic cardiomyopathy (HCM)</p>	<p><b>NB.</b> While many consider existing HCM or malignancy as relative contraindications to GHT, there are no data to support this claim. Additionally, there is no evidence of an increased risk of HCM or malignancy developing in people with NS undertaking GHT.</p>
<ul style="list-style-type: none"> <li>Coagulation screening</li> </ul>	<p>Should be carried out at least once during mid/late childhood (5—11 years old), and before major surgery.</p> <p><b>ABNL</b> Aspirin should be withheld before any surgical interventions, as per standard practice.</p>



# Recommendations for the management of Noonan Syndrome

~ *in childhood (2)* ~

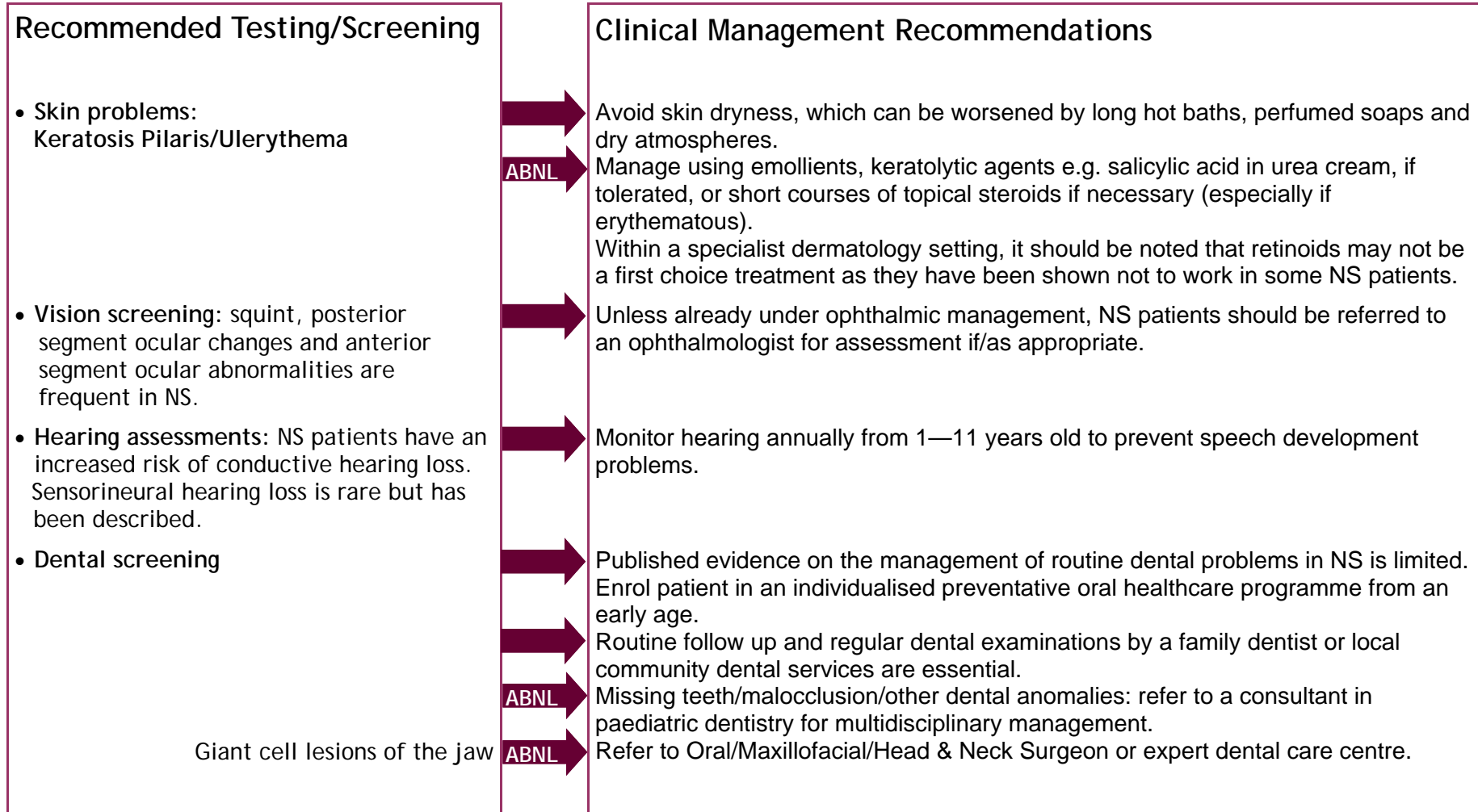
AGE 1-11

Recommended Testing/Screening	Clinical Management Recommendations
<ul style="list-style-type: none"> <li>• <b>Neuropsychological and Behavioural Issues:</b> hypotonia and motor delay are common in NS and can cause developmental delay.</li> </ul>	<p>Screening for developmental delay and full neuropsychological assessment at primary (to include speech acquisition) and secondary school entry, and if/when symptomatic. Assess intellectual/cognitive abilities with special attention for learning difficulties as a result of motor delay, executive dysfunctions and inattention.</p>
<ul style="list-style-type: none"> <li>• <b>Neurology</b>—potential complications in NS include seizures, craniosynostosis, hydrocephalus and Arnold Chiari Malformation.</li> </ul>	<p>Developmental delay caused by hypotonia will improve with occupational and physiotherapy. Referral for speech therapy if acquisition is delayed. Management of developmental delay will be as per the general population. Ongoing review and support of learning and development with further assessment of special educational needs as required.</p>
<ul style="list-style-type: none"> <li>• <b>Musculoskeletal</b></li> </ul>	<p>Low threshold for investigation of neurological symptoms e.g. consider Arnold-Chiari malformation and hydrocephalus if patient presents with headache or other neurological symptoms, and refer for MRI if suspected.</p>
<ul style="list-style-type: none"> <li>• <b>Feeding assessment:</b> if necessary—most feeding issues will have resolved by 18 months.</li> </ul>	<p>Monitor for scoliosis. Be aware that it can worsen with GHT.</p>
<ul style="list-style-type: none"> <li>• <b>Check for cryptorchidism</b></li> </ul>	<p>Talipes occurs in 5 % of NS patients and should be managed as per the general population.</p>
<ul style="list-style-type: none"> <li>• <b>Lymphoedema:</b> There is an increased risk of developing lymphoedema in NS, throughout childhood and later life.</li> </ul>	<p>Refer for occupational therapy for management of hypermobility. Refer for dietary assessment and evaluation of swallowing if needed. Refer to speech therapist for management if necessary. Frequent vomiting should prompt investigation for gastro-oesophageal reflux and malrotation. Treat with anti-reflux measures. Persistent vomiting or food refusal may require tube feeding (although this is rare). Manage in the standard way at the appropriate time. Management should be the same as for general population.</p>

# Recommendations for the management of Noonan Syndrome

~ *in childhood (3)* ~

AGE 1–11



**! Anaesthesia**  
*NS can cause coagulation difficulties that should be evaluated prior to surgical procedures so that care, including anaesthesia, can be planned accordingly.*  
*Patients with NS and haemodynamically significant cardiac involvement such as severe hypertrophic cardiomyopathy need to be treated according to the usual principles for patients with such cardiovascular risk factors.*  
*Patients with NS may have craniofacial and/or vertebral anomalies that could affect intubation or the administration of spinal anaesthesia.*

# Recommendations for the management of Noonan Syndrome

~ *in adolescence (1)* ~

Recommended Testing/Screening	Clinical Management Recommendations
<ul style="list-style-type: none"> <li>Echocardiogram (ECHO)</li> </ul>	<p>An ECHO in adolescence is recommended as this is when familial HCM may first be identified.</p> <p>Continued cardiac follow up throughout adolescence is important.</p>
<ul style="list-style-type: none"> <li>Puberty</li> </ul>	<p>The likelihood of delayed puberty should be anticipated, and appropriate education and counselling provided around this issue.</p>
<ul style="list-style-type: none"> <li>Neuropsychological and Behavioural Issues</li> </ul>	<p>Access to social skills training, and programmes to teach basic self help and daily living skills, if required.</p> <p>Screen for mood and anxiety disorders if suspected.</p>
<ul style="list-style-type: none"> <li>Neurology—potential complications in NS include seizures, craniosynostosis, hydrocephalus and Arnold Chiari malformation)</li> </ul>	<p>If necessary, consider pharmacological management.</p> <p>No routine screening is recommended, however there should be a low threshold for investigation of neurological symptoms e.g. consider Arnold-Chiari malformation and hydrocephalus if patient presents with headache or other neurological symptoms, and refer for MRI if suspected.</p>
<ul style="list-style-type: none"> <li>Coagulation screening</li> </ul>	<p>Management of specific complications, including epilepsy, will be as per the general population.</p> <p>Screen before any surgical intervention, and withhold aspirin prior to surgery, as per standard practice.</p>
<ul style="list-style-type: none"> <li>Musculoskeletal</li> </ul>	<p>Monitor for scoliosis.</p> <p>Be aware that scoliosis can worsen with GHT and in adolescence.</p>
<ul style="list-style-type: none"> <li>Thyroid screening</li> </ul>	<p>Screen blood for thyroid abnormalities every 3—5 years in older children and adults.</p> <p>Manage anomalies as in general population.</p>
<ul style="list-style-type: none"> <li>Lymphoedema</li> </ul>	<p>There is an increased risk of developing lymphoedema in NS, throughout childhood and later life.</p> <p>Management should be the same as for general population.</p>

# Recommendations for the management of Noonan Syndrome

~ in adolescence (2) ~

AGE 11-18

Recommended Testing/Screening	Clinical Management Recommendations
<ul style="list-style-type: none"> <li>• Skin problems: Keratosis Pilaris/Ulerythema</li> </ul>	<p>Avoid skin dryness, which can be worsened by long hot baths, perfumed soaps and dry atmospheres.</p> <p>Manage using emollients, keratolytic agents e.g. salicylic acid in urea cream, if tolerated, or short courses of topical steroids if necessary (especially if erythematous). Within a specialist dermatology setting, it should be noted that retinoids may not be a first choice treatment as they have been shown not to work in some NS patients.</p>
<ul style="list-style-type: none"> <li>• Vision screening: squint, posterior segment ocular changes and anterior segment ocular abnormalities have been described in NS.</li> </ul>	<p>Unless already under ophthalmic management, NS patients should be referred to an ophthalmologist for assessment if/as appropriate.</p>
<ul style="list-style-type: none"> <li>• Dental screening</li> </ul>	<p>Published evidence on the management of routine dental problems in NS is limited. Routine follow up and regular dental examinations by a family dentist or local community dental services are essential.</p>
<p>Giant cell lesions of the jaw</p>	<p>Missing teeth/malocclusion/other dental anomalies: refer to a consultant in paediatric dentistry for multidisciplinary management.</p> <p>Refer to Oral/Maxillofacial/Head &amp; Neck Surgeon or expert dental care centre.</p>
<ul style="list-style-type: none"> <li>• Genetic counselling</li> </ul>	<p>Refer for genetic counselling, mutation testing and discussion of risks to children and options in pregnancy, at an appropriate time.</p>

**! Anaesthesia**  
*NS can cause coagulation difficulties that should be evaluated prior to surgical procedures so that care, including anaesthesia, can be planned accordingly.*  
*Patients with NS and haemodynamically significant cardiac involvement such as severe hypertrophic cardiomyopathy need to be treated according to the usual principles for patients with such cardiovascular risk factors.*  
*Patients with NS may have craniofacial and/or vertebral anomalies that could affect intubation or the administration of spinal anaesthesia.*

# Recommendations for the management of Noonan Syndrome

~ *in adulthood (1)* ~

AGE 18+

Recommended Testing/Screening	Clinical Management Recommendations
• Genetic counselling	Refer for genetic counselling, mutation testing and discussion of risks to children and options in pregnancy.
• Fertility issues	Care providers should be made aware of the increased risk of infertility in males with NS, and not just in those with cryptorchidism.
• In pregnancy	Refer to a fertility clinic or endocrinologist if necessary.
Fetal considerations	Prenatal features include; polyhydramnios, increased nuchal translucency, hydrops fetalis and cystic hygroma, with or without associated ascites, pleural effusion, renal abnormalities and congenital heart defects.
Maternal considerations	Chorionic villus sampling (CVS) or amniocentesis is possible—referral to a clinical genetics service preconceptually is ideal— if parental mutation is known and couple wish for a prenatal diagnosis.
• Neuropsychological and Behavioural Issues	Ultrasounds at 12—14 and 20 weeks and undertake mutation analysis if parental mutation known and clinical features are suggestive, if required.
• Neurology—potential complications in NS include seizures, craniosynostosis, hydrocephalus and Arnold Chiari malformation)	Potential difficulties, for example those arising from coagulation defects during childbirth, should be considered and planned for as appropriate.
• Coagulation screening	Repeat neuropsychological assessment if patient is symptomatic of mood/anxiety disorder(s), or if cognitive impairments are suspected.
• Cardiac screening	Pay extra attention to the evaluation of social cognition and social embedding. Consider the risk of under-diagnosing because of problems in expressing emotions. If necessary, consider pharmacological management.
Pulmonary artery intervention	Facilitate access to support for employment, self help and independent living. Social skills intervention as needed.
	Low threshold for investigation of neurological symptoms e.g. consider Arnold-Chiari malformation and hydrocephalus if patient presents with headache or other neurological symptoms, and refer for MRI if suspected.
	Management of specific complications, including epilepsy, will be as per the general population.
	Screen before any surgical intervention, and withhold aspirin prior to surgery, as per standard practice.
	Newly diagnosed adults: full cardiac evaluation including ECHO.
	Previously diagnosed adults: regular cardiac assessment of existing heart disease, or cardiac evaluation incase aortic disease missed previously.
	Follow up for pulmonary valve insufficiency.

# Recommendations for the management of Noonan Syndrome

~ *in adulthood (2)* ~

AGE **18+**

Recommended Testing/Screening		Clinical Management Recommendations
• Thyroid screening	→	Screen blood for thyroid abnormalities every 3—5 years.
	→ ABNL	Manage anomalies as in general population.
• Lymphoedema	→	There is an increased risk of developing lymphoedema in NS, throughout adulthood.
	→ ABNL	Management should be the same as for general population.
• Skin problems: Keratosis Pilaris/Ulerythema	→	Avoid skin dryness, which can be worsened by long hot baths, perfumed soaps and dry atmospheres.
	→ ABNL	Manage using emollients, keratolytic agents e.g. salicylic acid in urea cream, if tolerated, or short courses of topical steroids if necessary (especially if erythematous).
	→	Within a specialist dermatology setting, it should be noted that retinoids may not be a first choice treatment as they have been shown not to work in some NS patients.
• Vision screening: squint, posterior segment ocular changes and anterior segment ocular abnormalities have been described in NS.	→	Unless already under ophthalmic management, NS patients should be referred to an ophthalmologist for assessment if/as appropriate.
• Dental screening	→	Published evidence on the management of routine dental problems in NS is limited.
	→	Routine follow up and regular dental examinations by a family dentist or local community dental services are essential.
	→ ABNL	Missing teeth/malocclusion/other dental anomalies: refer to a consultant in dentistry for multidisciplinary management.
Giant cell lesions of the jaw	→ ABNL	Refer to Oral/Maxillofacial/Head & Neck Surgeon or expert dental care centre.

**! Anaesthesia**  
*NS can cause coagulation difficulties that should be evaluated prior to surgical procedures so that care, including anaesthesia, can be planned accordingly.*  
*Patients with NS and haemodynamically significant cardiac involvement such as severe hypertrophic cardiomyopathy need to be treated according to the usual principles for patients with such cardiovascular risk factors.*  
*Patients with NS may have craniofacial and/or vertebral anomalies that could affect intubation or the administration of spinal anaesthesia.*

















# References 1

## General papers & Guidelines

- Allanson, J. E. (1987). "Noonan syndrome." *Journal of Medical Genetics* 24(1): 9-13.
- Allanson, J. E. (2007). "Noonan syndrome." *Am J Med Genet C Semin Med Genet* 145C(3): 274-9.
- Noonan, J. A. (1994). "Noonan Syndrome: An Update and Review for the Primary Pediatrician." *Clinical Pediatrics* 33(9): 548-555.
- Sharland, M., M. Burch, et al. (1992). "A clinical study of Noonan syndrome." *Arch Dis Child* 67(2): 178-83.
- van der Burgt, I. (2007). "Noonan syndrome." *Orphanet J Rare Dis* 2: 4.
- Zenker, M. E. (2009). "Noonan syndrome and related disorders: A matter of deregulated RAS Signaling." *Monographs in Human Genetics* 17(Karger).

## Anaesthesia

- Campbell, A. M. and J. D. Bousfield (1992). "Anaesthesia in a patient with Noonan's syndrome and cardiomyopathy." *Anaesthesia* 47(2): 131-3.
- Grange, C. S., R. Heid, et al. (1998). "Anaesthesia in a parturient with Noonan's syndrome." *Can J Anaesth* 45(4): 332-6.
- Lee, C. K., B. S. Chang, et al. (2001). "Spinal deformities in Noonan syndrome: a clinical review of sixty cases." *J Bone Joint Surg Am* 83-A(10): 1495-502.
- Macksey, L. F. and B. White (2007). "Anesthetic management in a pediatric patient with Noonan syndrome, mastocytosis, and von Willebrand disease: a case report." *AANA J* 75(4): 261-4.
- McBain, J., E. G. Lemire, et al. (2006). "Epidural labour analgesia in a parturient with Noonan syndrome: a case report." *Can J Anaesth* 53(3): 274-8.
- Ng, C. H., B. Singh, et al. (2005). "Dental anaesthesia in a patient with Noonan syndrome." *Br J Oral Maxillofac Surg* 43(3): 267-8.
- Sharma, P. R., U. M. MacFadyen, et al. (2007). "Dental management of a child patient with Noonan's syndrome." *Dent Update* 34(2): 117-8, 120.

## Behaviour, Developmental Delay & Communication

- Collins, E. and G. Turner (1973). "The Noonan syndrome--a review of the clinical and genetic features of 27 cases." *J Pediatr* 83(6): 941-50.
- Cornish, K. M. (1996). "Verbal-performance discrepancies in a family with Noonan syndrome." *Am J Med Genet* 66(2): 235-6.
- Ghaziuddin, M., B. Bolyard, et al. (1994). "Autistic disorder in Noonan syndrome." *J Intellect Disabil Res* 38 ( Pt 1): 67-72.
- Horiguchi, T. and K. Takeshita (2003). "Neuropsychological developmental change in a case with Noonan syndrome: longitudinal assessment." *Brain Dev* 25(4): 291-3.
- Lee, D. A., S. Portnoy, et al. (2005). "Psychological profile of children with Noonan syndrome." *Dev Med Child Neurol* 47(1): 35-8.
- Money, J. and M. E. Kalus, Jr. (1979). "Noonan's syndrome. IQ and specific disabilities." *Am J Dis Child* 133(8): 846-50.
- Money, J. and V. Duch (1981). "Adolescent males with Noonan's syndrome: behavioral and erotosexual status." *J Pediatr Psychol* 6(3): 265-74.
- Pierpont, E. I., M. E. Pierpont, et al. (2009). "Genotype differences in cognitive functioning in Noonan syndrome." *Genes, Brain and Behavior* 8(3): 275-282.
- Sarimski, K. (2000). "Developmental and behavioural phenotype in Noonan syndrome?" *Genet Couns* 11(4): 383-90.
- Troyer, A. K. and M. Joschko (1997). "Cognitive Characteristics Associated with Noonan Syndrome: Two Case Reports." *Child Neuropsychology* 3 (3): 199 - 205.
- van der Burgt, I. (2007). "Noonan syndrome." *Orphanet J Rare Dis* 2: 4.
- Verhoeven, W. M., J. L. Hendriks, et al. (2004). "Alexithymia in Noonan syndrome." *Genet Couns* 15(1): 47-52.
- Verhoeven, W., E. Wingbermuehle, et al. (2008). "Noonan syndrome: psychological and psychiatric aspects." *Am J Med Genet A* 146A(2): 191-6.
- Wilson, M. and A. Dyson (1982). "Noonan syndrome: speech and language characteristics." *J Commun Disord* 15(5): 347-52.
- Wingbermuehle, E., J. Egger, et al. (2009). "Neuropsychological and Behavioral Aspects of Noonan Syndrome." *Hormone Research in Paediatrics* 72 (Suppl. 2): 15-23.
- Wood, A., A. Massarano, et al. (1995). "Behavioural aspects and psychiatric findings in Noonan's syndrome." *Arch Dis Child* 72(2): 153-5.



## References 2

### Bleeding

- Alanay, Y., S. Balci, et al. (2004). "Noonan syndrome and systemic lupus erythematosus: presentation in childhood." Clin Dysmorphol 13(3): 161-3.
- Bertola, D. R., J. D. Carneiro, et al. (2003). "Hematological findings in Noonan syndrome." Rev Hosp Clin Fac Med Sao Paulo 58(1): 5-8.
- de Haan, M., J. J. vd Kamp, et al. (1988). "Noonan syndrome: partial factor XI deficiency." Am J Med Genet 29(2): 277-82.
- Dineen, R. A. and R. K. Lenthall (2004). "Aneurysmal sub-arachnoid haemorrhage in patients with Noonan syndrome: a report of two cases and review of neurovascular presentations in this syndrome." Neuroradiology 46(4): 301-5.
- Emmerich, J., M. Aiach, et al. (1992). "Noonan's syndrome and coagulation-factor deficiencies." Lancet 339(8790): 431.
- Flick, J. T., A. K. Singh, et al. (1991). "Platelet dysfunction in Noonan's syndrome. A case with a platelet cyclooxygenase-like deficiency and chronic idiopathic thrombocytopenic purpura." Am J Clin Pathol 95(5): 739-42.
- Kitchens, C. S. and J. A. Alexander (1983). "Partial deficiency of coagulation factor XI as a newly recognized feature of Noonan syndrome." J Pediatr 102(2): 224-7.
- Lisbona, M. P., M. Moreno, et al. (2009). "Noonan syndrome associated with systemic lupus erythematosus." Lupus 18(3): 267-9.
- Massarano, A. A., A. Wood, et al. (1996). "Noonan syndrome: coagulation and clinical aspects." Acta Paediatr 85(10): 1181-5.
- Sgouros, S. N., G. Karamanolis, et al. (2004). "Postbiopsy intramural hematoma of the duodenum in an adult with Noonan's syndrome." J Gastroenterol Hepatol 19(10): 1217-9.
- Sharland, M., M. A. Patton, et al. (1992). "Coagulation-factor deficiencies and abnormal bleeding in Noonan's syndrome." Lancet 339(8784): 19-21.
- Sharma, P. R., U. M. MacFadyen, et al. (2007). "Dental management of a child patient with Noonan's syndrome." Dent Update 34(2): 117-8, 120.
- Singer, S. T., D. Hurst, et al. (1997). "Bleeding disorders in Noonan syndrome: three case reports and review of the literature." J Pediatr Hematol Oncol 19(2): 130-4.
- Tofil, N. M., M. K. Winkler, et al. (2005). "The use of recombinant factor VIII in a patient with Noonan syndrome and life-threatening bleeding." Pediatr Crit Care Med 6(3): 352-4.
- Witt, D. R., B. C. McGillivray, et al. (1988). "Bleeding diathesis in Noonan syndrome: a common association." Am J Med Genet 31(2): 305-17.

### Cancer & Tumours

- Addante, R. R. and G. H. Breen (1996). "Cherubism in a patient with Noonan's syndrome." J Oral Maxillofac Surg 54(2): 210-3.
- Aggarwal, A., J. Krishnan, et al. (2001). "Noonan's syndrome and seminoma of undescended testicle." South Med J 94(4): 432-4.
- Attard-Montalto, S. P., J. E. Kingston, et al. (1994). "Noonan's syndrome and acute lymphoblastic leukaemia." Med Pediatr Oncol 23(4): 391-2.
- Bader-Meunier, B., G. Tchernia, et al. (1997). "Occurrence of myeloproliferative disorder in patients with Noonan syndrome." J Pediatr 130(6): 885-9.
- Chantrain, C. F., P. Jijon, et al. (2007). "Therapy-related acute myeloid leukemia in a child with Noonan syndrome and clonal duplication of the germline PTPN11 mutation." Pediatr Blood Cancer 48(1): 101-4.
- Cheong, J. L. and M. H. Moorkamp (2007). "Respiratory failure, juvenile myelomonocytic leukemia, and neonatal Noonan syndrome." J Pediatr Hematol Oncol 29(4): 262-4.
- Choong, K., M. H. Freedman, et al. (1999). "Juvenile myelomonocytic leukemia and Noonan syndrome." J Pediatr Hematol Oncol 21(6): 523-7.
- Connor, J. M., D. A. Evans, et al. (1982). "Multiple odontogenic keratocysts in a case of the Noonan syndrome." Br J Oral Surg 20(3): 213-6.
- Cotton, J. L. and R. G. Williams (1995). "Noonan syndrome and neuroblastoma." Arch Pediatr Adolesc Med 149(11): 1280-1.
- de Lange, J., H. P. van den Akker, et al. (2007). "Central giant cell granuloma of the jaw: a review of the literature with emphasis on therapy options." Oral Surg Oral Med Oral Pathol Oral Radiol Endod 104(5): 603-15.
- de Lange, J. and H. P. van der Akker (2006). "Noonan syndrome with giant cell lesions." Int J Paediatr Dent 16(1): 69.
- Dotters, D. J., W. C. Fowler, Jr., et al. (1986). "Argon laser therapy of vulvar angiokeratoma." Obstet Gynecol 68(3 Suppl): 56S-59S.

## References 3

### Cancer and tumours continued...

- Edwards, P. C., J. Fox, et al. (2005). "Bilateral central giant cell granulomas of the mandible in an 8-year-old girl with Noonan syndrome (Noonan-like/multiple giant cell lesion syndrome)." Oral Surg Oral Med Oral Pathol Oral Radiol Endod 99(3): 334-40.
- Fryssira, H., G. Leventopoulos, et al. (2008). "Tumor development in three patients with Noonan syndrome." Eur J Pediatr 167(9): 1025-31.
- Fukuda, M., K. Horibe, et al. (1997). "Spontaneous remission of juvenile chronic myelomonocytic leukemia in an infant with Noonan syndrome." J Pediatr Hematol Oncol 19(2): 177-9.
- Johannes, J. M., E. R. Garcia, et al. (1995). "Noonan's syndrome in association with acute leukemia." Pediatr Hematol Oncol 12(6): 571-5.
- Jung, A., S. Bechthold, et al. (2003). "Orbital rhabdomyosarcoma in Noonan syndrome." J Pediatr Hematol Oncol 25(4): 330-2.
- Khan, S., H. McDowell, et al. (1995). "Vaginal rhabdomyosarcoma in a patient with Noonan syndrome." J Med Genet 32(9): 743-5.
- Kondoh, T., E. Ishii, et al. (2003). "Noonan syndrome with leukaemoid reaction and overproduction of catecholamines: a case report." Eur J Pediatr 162(7-8): 548-9.
- Kratz, C. P. and C. M. Niemeyer (2005). "Juvenile myelomonocytic leukemia." Hematology 10 Suppl 1: 100-3.
- Lee, S. M. and J. C. Cooper (2005). "Noonan syndrome with giant cell lesions." Int J Paediatr Dent 15(2): 140-5.
- Lee, C. K., B. S. Chang, et al. (2001). "Spinal deformities in Noonan syndrome: a clinical review of sixty cases." J Bone Joint Surg Am 83-A(10): 1495-502.
- Lopez-Miranda, B., S. J. Westra, et al. (1997). "Noonan syndrome associated with neuroblastoma: a case report." Pediatr Radiol 27(4): 324-6.
- Matsubara, K., H. Yabe, et al. (2005). "Acute myeloid leukemia in an adult Noonan syndrome patient with PTPN11 mutation." Am J Hematol 79(2): 171-2.
- Meyer, W. R. and D. J. Dotters (1996). "Laser treatment of recurrent vulvar angiokeratoma associated with Noonan syndrome." Obstet Gynecol 87 (5 Pt 2): 863-5.
- Moschovi, M., V. Touliaou, et al. (2007). "Rhabdomyosarcoma in a patient with Noonan syndrome phenotype and review of the literature." J Pediatr Hematol Oncol 29(5): 341-4.
- Mutesa, L., G. Pierquin, et al. (2008). "Germline PTPN11 missense mutation in a case of Noonan syndrome associated with mediastinal and retroperitoneal neuroblastic tumors." Cancer Genet Cytogenet 182(1): 40-2.
- Piombo, M., C. Rosanda, et al. (1993). "Acute lymphoblastic leukemia in Noonan syndrome: report of two cases." Med Pediatr Oncol 21(6): 454-5.
- Roti, G., R. La Starza, et al. (2006). "Acute lymphoblastic leukaemia in Noonan syndrome." Br J Haematol 133(4): 448-50.
- Schuettelz, L. G., S. McDonald, et al. (2009). "Pilocytic astrocytoma in a child with Noonan syndrome." Pediatr Blood Cancer 53(6): 1147-9.
- Seeliger, T., J. U. Voigt, et al. (2004). "Pulsating thoracic tumor caused by extragenital endometriosis in a patient with Noonan syndrome." Ann Thorac Surg 77(6): 2204-6.
- Sherman, C. B., A. Ali-Nazir, et al. (2009). "Primary mixed glioneuronal tumor of the central nervous system in a patient with noonan syndrome: a case report and review of the literature." J Pediatr Hematol Oncol 31(1): 61-4.
- Sidwell, R. U., P. Rouse, et al. (2008). "Granular cell tumor of the scrotum in a child with Noonan syndrome." Pediatr Dermatol 25(3): 341-3.
- Silvio, F., L. Carlo, et al. (2002). "Transient abnormal myelopoiesis in Noonan syndrome." J Pediatr Hematol Oncol 24(9): 763-4.
- Swanson, K. D., J. M. Winter, et al. (2008). "SOS1 mutations are rare in human malignancies: implications for Noonan Syndrome patients." Genes Chromosomes Cancer 47(3): 253-9.
- Ucar, B., A. Okten, et al. (1998). "Noonan syndrome associated with central giant cell granuloma." Clin Genet 53(5): 411-4.

### Cardiac

- Abadir, S., T. Edouard, et al. (2007). "Severe aortic valvar stenosis in familial Noonan syndrome with mutation of the PTPN11 gene." Cardiol Young 17(1): 95-7.
- Brown, J. R. and G. Plotnick (2008). "Pulmonary Artery Aneurysm as a Cause for Chest Pain in a Patient with Noonan's Syndrome: A Case Report." Cardiology 110(4): 249-251.

## References 4

### Cardiac continued...

- Burch, M., M. Sharland, et al. (1993). "Cardiologic abnormalities in Noonan syndrome: phenotypic diagnosis and echocardiographic assessment of 118 patients." *J Am Coll Cardiol* 22(4): 1189-92.
- Burch, T. M., F. X. McGowan, Jr., et al. (2008). "Congenital Supravalvular Aortic Stenosis and Sudden Death Associated with Anesthesia: What's the Mystery?" *Anesth Analg* 107(6): 1848-1854.
- Heuschmann, D., O. Butenandt, et al. (1996). "Left ventricular volume and mass in children on growth hormone therapy compared with untreated children." *European Journal of Pediatrics* 155(2): 77-80.
- Holt, S., Ryan, W.F., Kirkham, N., Coulshed, N. (1979). "Noonan's Syndrome and Cyanotic Congenital Heart Disease." *Acta Cardiologica* XXXIV(3): 167-177.
- Hudsmith, L., S. Petersen, et al. (2006). "Hypertrophic cardiomyopathy in Noonan Syndrome closely mimics familial hypertrophic cardiomyopathy due to sarcomeric mutations." *The International Journal of Cardiovascular Imaging (formerly Cardiac Imaging)* 22(3): 493-495.
- Kelnar, C. J. H. (2003). The role of somatropin therapy in children with Noonan syndrome. *Treat Endocrinol.* 2003;2(3):165-72.
- Kelnar, C. J. H. (2000). "Growth Hormone Therapy in Noonan Syndrome." *Hormone Research in Paediatrics* 53(Suppl. 1): 77-81.
- Kurose, A., O. Kotaro, et al. (2000). "Dilated cardiomyopathy in Noonan's Syndrome: A first autopsy case." *Human pathology* 31(6): 764-767.
- Leye, M., G. Calcagni, et al. (2009). "Coronary myocardial bridging in Noonan syndrome: definitive diagnosis with high-resolution CT." *Br J Radiol* 82(973): e8-10.
- Marino, B., M. C. Digilio, et al. (1999). "Congenital heart diseases in children with Noonan syndrome: An expanded cardiac spectrum with high prevalence of atrioventricular canal." *J Pediatr* 135(6): 703-6.
- Noonan, J. A. (2005). "Noonan syndrome and related disorders." *Progress in Pediatric Cardiology* 20(2): 177-185.
- Noordam, C., J. M. T. Draaisma, et al. (2001). "Effects of Growth Hormone Treatment on Left Ventricular Dimensions in Children with Noonan's Syndrome." *Hormone Research in Paediatrics* 56(3-4): 110-113.
- Ostman-Smith, I., G. Wettrell, et al. (2005). "Echocardiographic and electrocardiographic identification of those children with hypertrophic cardiomyopathy who should be considered at high-risk of dying suddenly." *Cardiology in the Young* 15(06): 632-642.
- Pandit, B., A. Sarkozy, et al. (2007). "Gain-of-function RAF1 mutations cause Noonan and LEOPARD syndromes with hypertrophic cardiomyopathy." *Nat Genet* 39(8): 1007-1012.
- Raaijmakers, R., C. Noordam, et al. (2008). "Are ECG abnormalities in Noonan syndrome characteristic for the syndrome?" *European Journal of Pediatrics* 167(12): 1363-1367.
- Shaw, A. C., K. Kalidas, et al. (2007). "The natural history of Noonan syndrome: a long-term follow-up study." *Archives of Disease in Childhood* 92(2): 128-132.
- Silverman, B. L. and J. R. Friedlander (1997). "Is growth hormone good for the heart?" *The Journal of Pediatrics* 131(1, Supplement 1): S70-S74.
- Sznajder, Y., B. Keren, et al. (2007). "The Spectrum of Cardiac Anomalies in Noonan Syndrome as a Result of Mutations in the PTPN11 Gene." *Pediatrics* 119(6): e1325-1331.
- Yukio, I., S. Kyoko, et al. (2003). "Fibromuscular dysplasia of coronary arteries resulting in myocardial infarction associated with hypertrophic cardiomyopathy in Noonan's syndrome." *Human pathology* 34(3): 282-284.

## References 5

### Dental

- Barberia Leache, E., D. Saavedra Ontiveros, et al. (2003). "Etiopathogenic analysis of the caries on three patients with Noonan Syndrome." Med Oral 8(2): 136-42.
- Emral, M. E. and M. O. Akcam (2009). "Noonan syndrome: a case report." J Oral Sci 51(2): 301-6.
- Nelson, J. F., P. J. Tsaknis, et al. (1978). "Noonan's syndrome: report of a case with oral findings." J Oral Med 33(3): 94-6.
- Okada, M., N. Sasaki, et al. (2003). "Oral findings in Noonan syndrome: report of a case." J Oral Sci 45(2): 117-21.
- Ortega Ade, O., O. Guare Rde, et al. (2008). "Orofacial aspects in Noonan syndrome: 2 case report." J Dent Child (Chic) 75(1): 85-90.
- Sugar, A. W., A. Ezsias, et al. (1994). "Orthognathic surgery in a patient with Noonan's syndrome." J Oral Maxillofac Surg 52(4): 421-5.

### Diagnosis

- Achiron, R., J. Heggesh, et al. (2000). "Noonan syndrome: a cryptic condition in early gestation." Am J Med Genet 92(3): 159-65.
- Duncan, W. J., R. S. Fowler, et al. (1981). "A comprehensive scoring system for evaluating Noonan syndrome." Am J Med Genet 10(1): 37-50.
- Ferrero, G. B. et al. (2008). "Clinical and molecular characterization of 40 patients with Noonan syndrome." Eur J Med Genet 51(6): 566-72.
- Jongmans, M., B. Otten, et al. (2004). "Genetics and variation in phenotype in Noonan syndrome." Horm Res 62 Suppl 3: 56-9.
- Jorge, A. A. L., A. C. Malaquias, et al. (2009). "Noonan Syndrome and Related Disorders: A Review of Clinical Features and Mutations in Genes of the RAS/MAPK Pathway." Hormone Research in Paediatrics 71(4): 185-193.
- Narumi, Y., Y. Aoki, et al. (2008). "Clinical manifestations in patients with SOS1 mutations range from Noonan syndrome to CFC syndrome." J Hum Genet 53(9): 834-41.
- Neri, G., J. Allanson, et al. (2008). "No reason yet to change diagnostic criteria for Noonan, Costello and cardio-facio-cutaneous syndromes." J Med Genet 45(12): 832.
- Roberts, A. E., T. Araki, et al. (2007). "Germline gain-of-function mutations in SOS1 cause Noonan syndrome." Nat Genet 39(1): 70-4.
- Sharland, M., M. Morgan, et al. (1993). "Photoanthropometric study of facial growth in Noonan syndrome." Am J Med Genet 45(4): 430-6.
- Sharland, M., M. Morgan, et al. (1993). "Genetic counselling in Noonan syndrome." Am J Med Genet 45(4): 437-40.
- Shaw, A. C., K. Kalidas, et al. (2007). "The natural history of Noonan syndrome: a long-term follow-up study." Archives of Disease in Childhood 92(2): 128-132.
- Trambo, N. A., K. Iqbal, et al. (2002). "Unusual dysmorphic features in five patients with Noonan's syndrome: a brief review." J Paediatr Child Health 38(5): 521-5.
- van der Burgt, I. (2007). "Noonan syndrome." Orphanet J Rare Dis 2: 4.

### Gastrointestinal & Feeding

- Bitton, A., J. N. Keagle, et al. (2007). "Small bowel bezoar in a patient with Noonan syndrome: report of a case." MedGenMed 9(1): 34.
- Cumming, W. A. and J. S. Simpson (1977). "Intestinal diverticulosis in Noonan's syndrome." Br J Radiol 50(589): 64-5.
- Keberle, M., H. Mork, et al. (2000). "Computed tomography after lymphangiography in the diagnosis of intestinal lymphangiectasia with protein-losing enteropathy in Noonan's syndrome." Eur Radiol 10(10): 1591-3.
- Sarimski, K. (2000). "Developmental and behavioural phenotype in Noonan syndrome?" Genet Couns 11(4): 383-90.
- Shah, N., M. Rodriguez, et al. (1999). "Feeding difficulties and foregut dysmotility in Noonan's syndrome." Arch Dis Child 81(1): 28-31.
- Shaw, A. C., K. Kalidas, et al. (2007). "The natural history of Noonan syndrome: a long-term follow-up study." Archives of Disease in Childhood 92(2): 128-132.

## References 6

### Growth & Stature, Endocrine & Cryptorchidism

- Binder, G. (2009). "Noonan Syndrome, the RasMAPK Signalling Pathway and Short Stature." *Hormone Research in Paediatrics* 71(Suppl. 2): 64-70.
- Collins, E. and G. Turner (1973). "The Noonan syndrome--a review of the clinical and genetic features of 27 cases." *J Pediatr* 83(6): 941-50.
- Cotterill, A. M., W. J. McKenna, et al. (1996). "The short-term effects of growth hormone therapy on height velocity and cardiac ventricular wall thickness in children with Noonan's syndrome." *J Clin Endocrinol Metab* 81(6): 2291-7.
- Elsawi, M. M., J. P. Pryor, et al. (1994). "Genital tract function in men with Noonan syndrome." *J Med Genet* 31(6): 468-70.
- Kelnar, C. J. H. (2000). "Growth Hormone Therapy in Noonan Syndrome." *Hormone Research in Paediatrics* 53(Suppl. 1): 77-81.
- Kirk, J. M. W., P. R. Betts, et al. (2001). "Short stature in Noonan syndrome: response to growth hormone therapy." *Archives of Disease in Childhood* 84(5): 440-443.
- Limal, J.-M., B. Parfait, et al. (2006). "Noonan Syndrome: Relationships between Genotype, Growth, and Growth Factors." *J Clin Endocrinol Metab* 91(1): 300-306.
- MacFarlane, C. E., D. C. Brown, et al. (2001). "Growth hormone therapy and growth in children with Noonan's syndrome: results of 3 years' follow-up." *J Clin Endocrinol Metab* 86(5): 1953-6.
- Marcus, K. A., C. G. J. Sweep, et al. (2008). Impaired Sertoli cell function in males diagnosed with Noonan syndrome. *J Pediatr Endocrinol Metab*. Nov;21(11):1079-84.
- Nistal, M., R. Paniagua, et al. (1983). "Testicular biopsy and hormonal study in a male with Noonan's syndrome." *Andrologia* 15(5): 415-25.
- Nistal, M., R. Paniagua, et al. (1984). "Testicular lymphangiectasis in Noonan's syndrome." *J Urol* 131(4): 759-61.
- Noonan, J. A. (2006). "Noonan syndrome and related disorders: alterations in growth and puberty." *Rev Endocr Metab Disord* 7(4): 251-5.
- Noonan, J. A., R. Raaijmakers, et al. (2003). "Adult height in Noonan syndrome." *Am J Med Genet A* 123A(1): 68-71.
- Noordam, C., J. M. T. Draaisma, et al. (2001). "Effects of Growth Hormone Treatment on Left Ventricular Dimensions in Children with Noonan's Syndrome." *Hormone Research in Paediatrics* 56(3-4): 110-113.
- Noordam, C., I. van der Burgt, et al. (2001). "Growth hormone (GH) secretion in children with Noonan syndrome: frequently abnormal without consequences for growth or response to GH treatment." *Clin Endocrinol (Oxf)* 54(1): 53-9.
- Noordam, C., J. Span, et al. (2002). "Bone mineral density and body composition in Noonan's syndrome: effects of growth hormone treatment." *J Pediatr Endocrinol Metab* 15(1): 81-7.
- Noordam, C., P. G. Peer, et al. (2008). "Long-term GH treatment improves adult height in children with Noonan syndrome with and without mutations in protein tyrosine phosphatase, non-receptor-type 11." *Eur J Endocrinol* 159(3): 203-8.
- Ogawa, M., N. Moriya, et al. (2004). "Clinical evaluation of recombinant human growth hormone in Noonan syndrome." *Endocr J* 51(1): 61-8.
- Okuyama, A., N. Nishimoto, et al. (1981). "Gonadal findings in cryptorchid boys with Noonan's phenotype." *Eur Urol* 7(5): 274-7.
- Osio, D., J. Dahlgren, et al. (2005). "Improved final height with long-term growth hormone treatment in Noonan syndrome." *Acta Paediatr* 94(9): 1232-7.
- Padidela, R., C. Camacho-Hubner, et al. (2008). "Abnormal growth in noonan syndrome: genetic and endocrine features and optimal treatment." *Horm Res* 70(3): 129-36.
- Redman, J. F. (1973). "Noonan's syndrome and cryptorchidism." *J Urol* 109(5): 909-11.
- Romano, A. A., K. Dana, et al. (2009). "Growth Response, Near-Adult Height, and Patterns of Growth and Puberty in Patients with Noonan Syndrome Treated with Growth Hormone." *J Clin Endocrinol Metab* 94(7): 2338-2344.
- Sasagawa, I., T. Nakada, et al. (1994). "Gonadal function and testicular histology in Noonan's syndrome with bilateral cryptorchidism." *Arch Androl* 32(2): 135-40.
- Shaw, A. C., K. Kalidas, et al. (2007). "The natural history of Noonan syndrome: a long-term follow-up study." *Archives of Disease in Childhood* 92(2): 128-132.



## References 7

### Growth & Stature, Endocrine & Cryptorchidism continued...

- Theintz, G. and M. O. Savage (1982). "Growth and pubertal development in five boys with Noonan's syndrome." *Arch Dis Child* 57(1): 13-7.
- Walton-Betancourth, S., C. E. Martinelli, et al. (2007). "Excellent growth response to growth hormone therapy in a child with PTPN11-negative Noonan syndrome and features of growth hormone resistance." *J Endocrinol Invest* 30(5): 439-41.
- Witt, D. R., B. A. Keena, et al. (1986). "Growth curves for height in Noonan syndrome." *Clin Genet* 30(3): 150-3.

### Hearing

- Miura, M., I. Sando, et al. (2001). "Temporal bone histopathological study of Noonan syndrome." *Int J Pediatr Otorhinolaryngol* 60(1): 73-82.
- Qiu, W. W., S. S. Yin, et al. (1998). "Audiologic manifestations of Noonan syndrome." *Otolaryngol Head Neck Surg* 118(3 Pt 1): 319-23.
- Scheiber, C., A. Hirschfelder, et al. (2009). "Bilateral cochlear implantation in children with Noonan syndrome." *Int J Pediatr Otorhinolaryngol* 73(6): 889-94.

### Immune

- Alanay, Y., S. Balci, et al. (2004). "Noonan syndrome and systemic lupus erythematosus: presentation in childhood." *Clin Dysmorphol* 13(3): 161-3.
- Lopez-Rangel, E., P. N. Malleson, et al. (2005). "Systemic lupus erythematosus and other autoimmune disorders in children with Noonan syndrome." *Am J Med Genet A* 139(3): 239-42.
- Martin, D. M., C. F. Gencyuz, et al. (2001). "Systemic lupus erythematosus in a man with Noonan syndrome." *Am J Med Genet* 102(1): 59-62.

### Lymph

- Bloomfield, F. H., W. Hadden, et al. (1997). "Lymphatic dysplasia in a neonate with Noonan's syndrome." *Pediatr Radiol* 27(4): 321-3.
- Cheng, M. F., Y. W. Wu, et al. (2008). "Usefulness of lymphoscintigraphy in demonstrating lymphedema in patients with Noonan syndrome." *Clin Nucl Med* 33(3): 226-7.
- Evans, D. G., R. N. Lonsdale, et al. (1991). "Cutaneous lymphangioma and amegakaryocytic thrombocytopenia in Noonan syndrome." *Clin Genet* 39(3): 228-32.
- Fisher, E., E. B. Weiss, et al. (1982). "Spontaneous chylothorax in Noonan's syndrome." *Eur J Pediatr* 138(3): 282-4.
- Lanning, P., S. Simila, et al. (1978). "Lymphatic abnormalities in Noonan's syndrome." *Pediatr Radiol* 7(2): 106-9.
- Miller, M. and A. C. Motulsky (1978). "Noonan syndrome in an adult family presenting with chronic lymphedema." *Am J Med* 65(2): 379-83.
- Ogata, T., S. Sato, et al. (2003). "Lymphstasis in a boy with Noonan syndrome: implication for the development of skeletal features." *Endocr J* 50(3): 319-24.
- Phillips, W. G., M. G. Dunnill, et al. (1993). "Orbital oedema: an unusual presentation of Noonan's syndrome." *Br J Dermatol* 129(2): 190-2.
- Scalzetti, E. M., E. R. Heitzman, et al. (1991). "Developmental lymphatic disorders of the thorax." *Radiographics* 11(6): 1069-85.
- Vallet, H. L., P. G. Holtzapple, et al. (1972). "Noonan syndrome with intestinal lymphangiectasis. A metabolic and anatomic study." *J Pediatr* 80(2): 269-74.
- White, S. W. (1984). "Lymphedema in Noonan's syndrome." *Int J Dermatol* 23(10): 656-7.
- Witt, D. R., H. E. Hoyme, et al. (1987). "Lymphedema in Noonan syndrome: clues to pathogenesis and prenatal diagnosis and review of the literature." *Am J Med Genet* 27(4): 841-56.

### Miscellaneous

- Qian, J. G. and X. J. Wang (2007). "Noonan syndrome and correction of the webbed neck." *J Plast Reconstr Aesthet Surg* 60(3): 316-9.

## References 8

### Neurology

- Dineen, R. A. and R. K. Lenthall (2004). "Aneurysmal sub-arachnoid haemorrhage in patients with Noonan syndrome: a report of two cases and review of neurovascular presentations in this syndrome." Neuroradiology 46(4): 301-5.
- Duenas, D. A., S. Preissig, et al. (1973). "Neurologic manifestations of the Noonan syndrome." South Med J 66(2): 193-6.
- Ganesan, V. and F. J. Kirkham (1997). "Noonan syndrome and moyamoya." Pediatr Neurol 16(3): 256-8.
- Hara, T., T. Sasaki, et al. (1993). "Noonan phenotype associated with intracerebral hemorrhage and cerebral vascular anomalies: case report." Surg Neurol 39(1): 31-6.
- Heye, N. and J. W. Dunne (1995). "Noonan's syndrome with hydrocephalus, hindbrain herniation, and upper cervical intracord cyst." J Neurol Neurosurg Psychiatry 59(3): 338-9.
- Hinnant, C. A. (1995). "Noonan syndrome associated with thromboembolic brain infarcts and posterior circulation abnormalities." Am J Med Genet 56(2): 241-4.
- Holder-Espinasse M, Winter RM: Type 1 Arnold-Chiari malformation and Noonan Syndrome. A new diagnostic feature. *Dysmorphol* 2003;12:275.
- Kratz, C. P., G. Zampino, et al. (2009). "Craniosynostosis in patients with Noonan syndrome caused by germline KRAS mutations." Am J Med Genet A 149A(5): 1036-40.
- Rudge, P., B. G. Neville, et al. (1974). "A case of Noonan's syndrome and hypoparathyroidism presenting with epilepsy." J Neurol Neurosurg Psychiatry 37(1): 108-11.
- Saito, Y., M. Sasaki, et al. (1997). "A case of Noonan syndrome with cortical dysplasia." Pediatr Neurol 17(3): 266-9.
- Schon, F., J. Bowler, et al. (1992). "Cerebral arteriovenous malformation in Noonan's syndrome." Postgrad Med J 68(795): 37-40.
- Schuster, J. M. and T. S. Roberts (1999). "Symptomatic moyamoya disease and aortic coarctation in a patient with Noonan's syndrome: strategies for management." Pediatr Neurosurg 30(4): 206-10.
- Tanaka, Y., M. Masuno, et al. (1999). "Noonan syndrome and cavernous hemangioma of the brain." Am J Med Genet 82(3): 212-4.
- Wilms, H., B. Neubauer, et al. (2002). "Cerebral occlusive artery disease in Noonan syndrome." Cerebrovasc Dis 14(2): 133-5.
- Yamashita, Y., A. Kusaga, et al. (2004). "Noonan syndrome, moyamoya-like vascular changes, and antiphospholipid syndrome." Pediatr Neurol 31(5): 364-6.

### Orthopaedic

- Butler, M. G., R. Kumar, et al. (2000). "Metacarpophalangeal pattern profile analysis in Noonan syndrome." Am J Med Genet 92(2): 128-31.
- Kobayashi, I., T. Aikawa, et al. (1986). "Noonan's syndrome with syringomyelia." Jpn J Psychiatry Neurol 40(1): 101-4.
- Lee, C. K., B. S. Chang, et al. (2001). "Spinal deformities in Noonan syndrome: a clinical review of sixty cases." J Bone Joint Surg Am 83-A(10): 1495-502.
- Mascheroni, E., M. C. Digilio, et al. (2008). "Pigmented villonodular synovitis in a patient with Noonan syndrome and SOS1 gene mutation." Am J Med Genet A 146A(22): 2966-7.
- Motohashi, O., R. Shirane, et al. (1993). "Tethered cord syndrome associated with male Turner's syndrome." Surg Neurol 40(1): 57-60.
- Naficy, S., N. T. Shepard, et al. (1997). "Multiple temporal bone anomalies associated with Noonan syndrome." Otolaryngol Head Neck Surg 116(2): 265-7.
- Sanford, R. A., R. Bowman, et al. (1999). "A 16-year-old male with Noonan's syndrome develops progressive scoliosis and deteriorating gait." Pediatr Neurosurg 30(1): 47-52.
- Sinis, N., T. I. Lanaras, et al. (2009). "Free latissimus dorsi flap with long venous grafts for closure of a soft tissue defect of the spine in a patient with Noonan's syndrome: a case report." Microsurgery 29(6): 486-9.
- Takagi, M., Y. Miyashita, et al. (2000). "Estrogen deficiency is a potential cause for osteopenia in adult male patients with Noonan's syndrome." Calcif Tissue Int 66(3): 200-3.

## References 9

### Prenatal

- Achiron, R., J. Heggesh, et al. (2000). "Noonan syndrome: a cryptic condition in early gestation." *Am J Med Genet* 92(3): 159-65.
- Bekker, M. N., A. T. Go, et al. (2007). "Persistence of nuchal edema and distended jugular lymphatic sacs in Noonan syndrome." *Fetal Diagn Ther* 22(4): 245-8.
- Cullimore, A. J., K. G. Smedstad, et al. (1999). "Pregnancy in women with Noonan syndrome: report of two cases." *Obstet Gynecol* 93(5 Pt 2): 813-6.
- Donnenfeld, A. E., M. A. Nazir, et al. (1991). "Prenatal sonographic documentation of cystic hygroma regression in Noonan syndrome." *Am J Med Genet* 39(4): 461-5.
- Gandhi, S. V., E. S. Howarth, et al. (2004). "Noonan syndrome presenting with transient cystic hygroma." *J Obstet Gynaecol* 24(2): 183-4.
- Graesslin, O., E. Derniaux, et al. (2007). "Characteristics and outcome of fetal cystic hygroma diagnosed in the first trimester." *Acta Obstet Gynecol Scand* 86(12): 1442-6.
- Houweling, A. C., Y. M. d. Mooij, et al. "Prenatal detection of Noonan syndrome by mutation analysis of the *PTPN11* and the *KRAS* genes." *Prenatal Diagnosis* 30(3): 284-286.
- Joo, J. G., A. Beke, et al. (2005). "Successful pregnancy in a Noonan syndrome patient after 3 unsuccessful pregnancies from severe fetal hydrops: a case report." *J Reprod Med* 50(5): 373-6.
- Kiyota, A., K. Tsukimori, et al. (2008). "Spontaneous resolution of cystic hygroma and hydrops in a fetus with Noonan's syndrome." *Fetal Diagn Ther* 24(4): 499-502.
- McBain, J., E. G. Lemire, et al. (2006). "Epidural labour analgesia in a parturient with Noonan syndrome: a case report." *Can J Anaesth* 53(3): 274-8.
- Schluter, G., M. Steckel, et al. (2005). "Prenatal DNA diagnosis of Noonan syndrome in a fetus with massive hygroma colli, pleural effusion and ascites." *Prenat Diagn* 25(7): 574-6.

### Renal

- Barker, M. and W. Engelhardt (2001). "Bilateral kidney duplication in familial Noonan's syndrome." *Clin Pediatr (Phila)* 40(4): 241-2.
- George, C. D., M. A. Patton, et al. (1993). "Abdominal ultrasound in Noonan syndrome: a study of 44 patients." *Pediatr Radiol* 23(4): 316-8.
- Gupta, A., A. Khaira, et al. (2009). "Noonan syndrome: crossed fused ectopic kidneys and focal segmental glomerulosclerosis-a rare association." *Clin Exp Nephrol*.
- Hellebusch, A. A. (1971). "Noonan syndrome with bilateral ureteral ectopia." *J Pediatr Surg* 6(4): 490.
- Raghavaiah, N. V. (1975). "Noonan's syndrome associated with cake kidney." *Urology* 5(5): 640-2.
- Raghavaiah, N. V. (1976). "Letter: Importance of Noonan's syndrome for the urologist." *J Urol* 116(1): 134.
- Semizel, E., O. M. Bostan, et al. (2007). "Bilateral multiple pulmonary arteriovenous fistulas and duplicated renal collecting system in a child with Noonan's syndrome." *Cardiology in the Young* 17(02): 229-231.
- Tejani, A., C. Del Rosario, et al. (1976). "Noonan's syndrome associated with polycystic renal disease." *J Urol* 115(2): 209-11.

### Skin

- Dotters, D. J., W. C. Fowler, Jr., et al. (1986). "Argon laser therapy of vulvar angiokeratoma." *Obstet Gynecol* 68(3 Suppl): 56S-59S.
- Fox, L. P., A. S. Geyer, et al. (2005). "Cutis verticis gyrata in a patient with Noonan syndrome." *Pediatr Dermatol* 22(2): 142-6.
- Hwang, S. and R. A. Schwartz (2008). "Keratosis pilaris: a common follicular hyperkeratosis." *Cutis* 82(3): 177-80.
- Lacombe, D., A. Taieb, et al. (1991). "Neonatal Noonan syndrome with a molluscoid cutaneous excess over the scalp." *Genet Couns* 2(4): 249-53.
- Lucker, G. P. and P. M. Steijlen (1994). "Widespread leucokeratosis in Noonan's syndrome." *Clin Exp Dermatol* 19(5): 414-7.
- Snell, J. A. and S. B. Mallory (1990). "Ulerythema ophryogenes in Noonan syndrome." *Pediatr Dermatol* 7(1): 77-8.
- Wyre, H. W., Jr. (1978). "Cutaneous manifestations of Noonan's syndrome." *Arch Dermatol* 114(6): 929-30.

## References 10

### Vision

- Ascaso, F. J., M. A. Del Buey, et al. (1993). "Noonan's syndrome with keratoconus and optic disc coloboma." Eur J Ophthalmol 3(2): 101-3.
- Au, Y. K., W. P. Collins, et al. (1997). "Spontaneous corneal rupture in Noonan syndrome. A case report." Ophthalmic Genet 18(1): 39-41.
- Carvalho, D. R., V. V. Alves, et al. (2003). "Noonan syndrome associated with unilateral iris coloboma and congenital chylothorax in an infant." Clin Dysmorphol 12(2): 143-4.
- Dollfus, H., L. Cantenot, et al. (2001). "Bilateral iridoretinal colobomas in a child with a Noonan phenotype." Clin Dysmorphol 10(4): 299-300.
- Elgohary, M. A., P. Bradshaw, et al. (2005). "Anterior uveitis and congenital fibrosis of the extraocular muscles in a patient with Noonan syndrome." J Postgrad Med 51(4): 319-21.
- Gravholt, C. H., M. Warburg, et al. (2002). "Mild Noonan phenotype associated with coloboma of the iris and choroid." Clin Dysmorphol 11(1): 75-7.
- Hill, V., W. Griffiths, et al. (2000). "Non-bullous congenital ichthyosiform erythroderma, with ocular albinism and Noonan syndrome." Clin Exp Dermatol 25(8): 611-4.
- Kerr, N. M. and A. L. Vincent (2009). "The Novel Concurrence of Noonan Syndrome and Bilateral Duane-Like Synkinesis." J Pediatr Ophthalmol Strabismus: 1-4.
- Kleanthous, L., D. Cruz, et al. (1987). "Colobomata associated with Noonan's syndrome." Postgrad Med J 63(741): 559-61.
- Lee, N. B., L. Kelly, et al. (1992). "Ocular manifestations of Noonan syndrome." Eye (Lond) 6 ( Pt 3): 328-34.
- Ram, S. P. and T. N. Krishna (1994). "Cardiopathy and ocular abnormalities in Noonan syndrome." Singapore Med J 35(4): 397-9.
- Reynolds, D. J., S. E. Rubin, et al. (2004). "Ocular manifestations of Noonan syndrome in the pediatric patient." J AAPOS 8(3): 282-3.
- Trambo, N. A., K. Iqbal, et al. (2002). "Unusual dysmorphic features in five patients with Noonan's syndrome: a brief review." J Paediatr Child Health 38(5): 521-5.

# Information for Parents

## Sources of Information and Support

Support for parents and other family members is cited in the literature as being an important provision for families affected by NS. The groups listed below are useful sources of support and information.

- **The Noonan Syndrome Support Group, Inc. ([www.noonansyndrome.org](http://www.noonansyndrome.org))**

The Noonan Syndrome Support Group is an international organisation, based in the US, that aims to support families affected by NS all over the world.

They offer information, support, and networking opportunities, and aim to improve awareness of NS and fund research into various aspects of the condition.

They regularly broadcast webchats with medical experts in NS, and run a well-used discussion forum.

For more information, or to join the Support Group, visit their website.

- **Contact a Family ([www.cafamily.org.uk](http://www.cafamily.org.uk))**

The Contact a Family website is for families who have a disabled child and whose who work with then or are interested to find out more about their needs. Contact A Family is the only UK charity providing support and advice to parents whatever the medical condition of their child, they have information on over 1,000 rare syndromes and can often put families in touch with each other.

- **Orphanet ([www.orpha.net](http://www.orpha.net))**

Orphanet is an online database of rare diseases and related services provided throughout Europe. It contains information on over 5,000 conditions, including Williams Syndrome, and lists specialised clinics, diagnostic tests, patient organisations, research projects, clinical trials and patient registries relating specifically to Noonan Syndrome.

- **Department of Health—Personalisation ([www.dh.gov.uk/en/SocialCare/Socialcarereform/Personalisation/index.htm](http://www.dh.gov.uk/en/SocialCare/Socialcarereform/Personalisation/index.htm))**

This website contains information on how the delivery of social care is being 'personalised'. This new approach uses individual budgets and direct payments to allow individuals more choice and control over the support they receive.

# Acknowledgements

- **The Noonan Syndrome Guideline Development Group**

Expert	Institution	Review Area
Bronwyn Kerr (Condition Lead)	St Mary's Hospital, Manchester, UK	Cancer, Tumours
Ineke van der Burgt (Condition Lead)	Radboud University, Nijmegen Medical Centre, Nijmegen, the Netherlands	Diagnosis, Prenatal
Sus Biswas	Manchester Royal Eye Hospital, UK	Vision
Jill Clayton-Smith	St Mary's Hospital, Manchester, UK	Skin
Jovanna Dahlgren	Queen Silvia Children's Hospital, Gothenburg, Sweden	Cryptorchidism, Growth & Stature, Endocrine
Bruce Gelb	Mount Sinai School of Medicine, New York City, USA	Cardiac, Anaesthesia
Malgorzata Krajewska-Walasek	Instytut Pomnick-Centrum Zdrowia Dziecka, Warsaw, Poland	Behaviour, Developmental delay, Communication
Jacqueline Noonan	University of Kentucky, USA	Cardiac
Cees Noordam	Radboud University, Nijmegen Medical Centre, Nijmegen, the Netherlands	Cryptorchidism, Growth & Stature, Endocrine
Nick Plant	Royal Manchester Children's Hospital, UK	Renal
Adam Shaw	Institute of Child Health, London, UK	Hearing and Neurology
Nalin Thakker	University of Manchester, UK	Dental
Brad Williamson	Salford Royal Hospital, UK	Orthopaedic
Ellen Wingbermuehle	Vincent van Gogh Institute for Psychiatry, Venray, the Netherlands	Behaviour, Developmental delay, Communication
Rob Wynn	Royal Manchester Children's Hospital, UK	Bleeding and Immune

- **The Noonan Syndrome Guideline Development Team**

Kate Strong, University of Manchester  
 Pam Griffiths, University of Manchester  
 Caroline Harrison, University of Manchester

- **DYSCERNE: A Network of Centres of Expertise in Dysmorphology ([www.dyscerne.org](http://www.dyscerne.org))**

- **Nowgen—A Centre for Genetics in Healthcare ([www.nowgen.org.uk](http://www.nowgen.org.uk))**

- **Novo Nordisk Inc. for the use of NS growth charts**

These guidelines were produced thanks to funding from DYSCERNE: A Network of Centre of Expertise for Dysmorphology (funded by the European Commission Public Health Executive Agency (DG Sanco) Project: 2006122).

**Document Title:** Management of Noonan Syndrome: A Clinical Guideline  
**Version:** 1  
**Created:** 15/2/2010  
**Reviewed:** 00/00/0000  
**Review Date:** 15/02/2011  
**Author:** DYSCERNE— Noonan Syndrome Guideline Development Group  
**Contact details:** [bronwyn.kerr@cmft.nhs.uk](mailto:bronwyn.kerr@cmft.nhs.uk)  
 University of Manchester © 2010